

# Is There a Relationship Between Maxillary Sinus Findings and Skeletal Malocclusion?

Sertac Aksakalli, DDS, PhD;<sup>1,\*</sup> Berza Sen Yilmaz, DDS, PhD;<sup>1</sup> Muhammet Birlik, DDS, PhD;<sup>1</sup> Ferit Dadasli;<sup>2</sup> and Esra Bolukbasi<sup>2</sup>

## ABSTRACT

**Objective:** No study has investigated the relationship between maxillary sinus findings and skeletal malocclusion based on cone-beam computed tomography (CBCT). The objectives of this study were to determine the relationship between the frequency of sinus findings and patients' skeletal malocclusion classification.

**Materials and Method:** A total of 105 CBCT scans were examined and divided into 3 groups according to skeletal classification. Two experienced observers reviewed the CBCT images and recorded all maxillary sinus findings. The patients' skeletal malocclusion, the thickness of the Schneiderian membrane, and the pathologic sinus findings were evaluated.

**Results:** The sinus findings were classified into 4 groups: 0 = no finding, 1 = mucosal thickening, 2 = partial opacification with liquid accumulation, and 3 = total opacification. The statistical analysis showed that there was no correlation between the skeletal malocclusion and pathological sinus findings. However, there were significant differences in the Schneiderian membrane thicknesses between the groups.

**Conclusion:** The Schneiderian membrane thickness was significantly different for Class II and Class III patients. There was no relationship between pathological sinus findings and skeletal malocclusions. (*Turkish J Orthod* 2015;28:44–47)

**KEY WORDS:** Malocclusion, Membrane, Sinus, Tomography

## INTRODUCTION

Cone-beam computed tomography (CBCT) is used for 3-dimensional imaging in orthodontics. CBCT provides detailed and essential data about dentomaxillofacial structures. Unlike computed tomography, CBCT has lower radiation doses for patients.<sup>1</sup> This advantage is important for choosing the appropriate imaging technique. When children are treated, radiographs produced for orthodontic purposes contribute to the radiation burden in young adults.<sup>2</sup> By selecting the ideal imaging system and the smallest field of view (FOV), which is the extent of the observable area, the as low as reasonably achievable (ALARA) principle may be satisfied. The ALARA principle is a radiation safety principle for minimizing radiation doses and a regulatory requirement for all radiation safety applications.

Data on the frequency of incidental findings related to maxillary sinus with CBCT imaging are limited in the orthodontic literature. The prevalence of mucosal thickening and the prevalence of cystic

lesion occurrence for maxillary sinus have been reported at 27% and 9%, respectively.<sup>3</sup> Researchers evaluated the findings of 500 CBCT scans and concluded that the ratio of incidental findings for orthodontic patients was 24.6%.<sup>4</sup> Another study, performed with magnetic resonance imaging, reported that the second highest prevalence was observed for maxillary sinuses.<sup>3</sup>

Sinus pathologies such as rhinosinusitis or sinusitis have many symptoms, including nasal congestion, nasal discharge, nasal purulence, and nasal obstruction.<sup>5</sup> Several etiologic factors such as incorrect breathing patterns and airway obstructions may contribute to the development of malocclusions.<sup>6</sup> Agren *et al.*<sup>7</sup> reported that with abnormal breathing, a growing child can reveal problems with craniofacial growth, such as vertical facial pattern

**\*Corresponding author:** Sertac Aksakalli, Bezmialem Vakif Univ., Dis Hekimligi Fak., Ortodonti AD, Vatan cad, Fatih, Istanbul, Turkey. Tel: 0090 533 354 8685 E-mail: sertacakskal@gmail.com

To cite this article: Aksakalli S, Yilmaz BS, Birlik M, Dadasli F, Bolukbasi E. Is there a relationship between maxillary sinus findings and skeletal malocclusion? *Turkish J Orthod.* 2015;28:44–47 (DOI: <http://dx.doi.org/10.13076/TJO-D-14-00027>)

Date Submitted: September 2014. Date Accepted: March 2015. Copyright 2015 by Turkish Orthodontic Society

<sup>1</sup>Assistant Professor, Bezmialem Vakif University, Faculty of Dentistry, Department of Orthodontics, Istanbul, Turkey

<sup>2</sup>PhD Student, Bezmialem Vakif University, Faculty of Dentistry, Department of Orthodontics, Istanbul, Turkey

and skeletal Class II malocclusion. The retrognathic mandible induces the backward position of the tongue and hyoid bone that can lead to a reduction in the upper airway volume.<sup>8</sup> Therefore, in this study, one of our objectives (the second objective) was to check for a correlation between skeletal malocclusion and sinus pathologies.

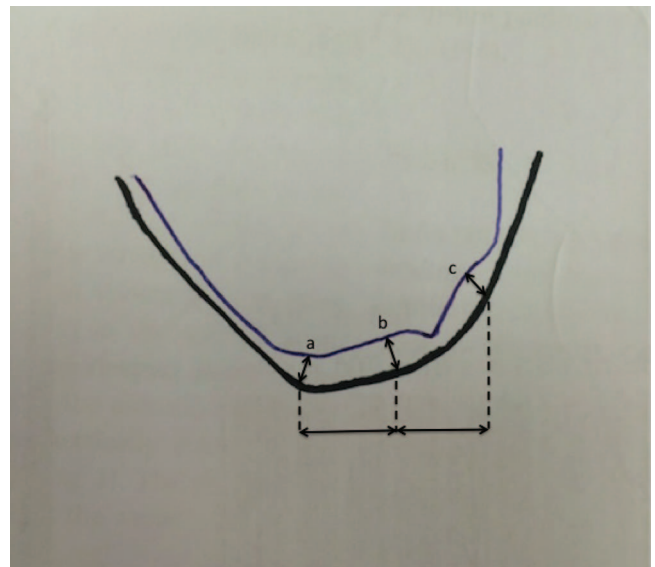
The increased use of CBCT by dentists and orthodontists offered an assessment of the prevalence of maxillary sinus findings allowing further evaluation. Signs of inflammation, obstruction, or acute infection in the maxillary sinus are relevant when a dentist or orthodontist plans orthodontic treatment or to prevent relapse after treatment.<sup>9</sup>

To the best of our knowledge, no study has evaluated the relationship between skeletal malocclusions and maxillary sinuses on CBCT scans. Therefore, the first objective of our study was to analyze the Schneiderian membrane thickness (the thickness of the lower part of the sinus membrane) and sinus pathologies. The second objective was to determine whether there is a correlation between skeletal malocclusions and sinus findings.

## MATERIALS AND METHODS

All CBCT scans performed for general dental purposes from March 2012 to March 2014 at the Faculty of Dentistry, Bezmialem Vakif University, were eligible for this study ( $n = 164$ ). The study protocol was approved by the Bezmialem Vakif University, Ethics Committee of Human Studies. Data presenting cleft lip and palate were excluded from the study ( $n = 11$ ). In addition, poor quality scans of the mandible only or only the upper jaw without the maxillary sinuses were excluded from the study ( $n = 48$ ). Thus, a total of 105 CBCT scans for 105 patients were eligible for further evaluation. The CBCT scans were divided into 3 groups according to the skeletal malocclusions: Class I, II, and III. Each group consisted of 35 patients. The mean age of the patients was  $24.5 \pm 6.9$  years. Gender classification revealed more men ( $n = 55$ ) than women ( $n = 50$ ).

All CBCT images were taken using a small FOV ( $6 \times 6$  or  $8 \times 8$  cm; Promax 3D, Planmeca Oy, Helsinki, Finland) and a voxel size of 0.125 mm. The data were reconstructed in 1:1 scaled slices and examined slice by slice in all 3 planes with the help of the Romexis viewer (Planmeca Oy, Helsinki, Finland). When needed, a magnifier and the ruler tool of the viewer were used.



**Figure 1.** Measurement of the thickness of the Schneiderian membrane at 3 locations on a schematic coronal view of the maxillary sinus. (b) Deepest point of the recess of the maxillary sinus; (a–c) 5 mm to the facial or palatal side.

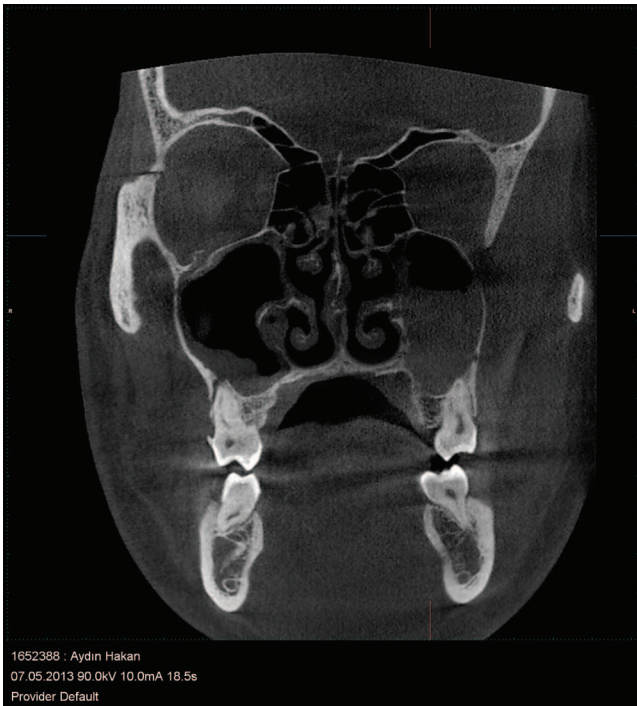
Two observers reviewed all CBCT scans independently. The reviewers checked and recorded all sinus findings and determined the patients' skeletal malocclusions via CBCT scans (according to the Steiner analysis and Wits appraisal). The pathological findings were classified into the following categories as described by Pazera *et al.*<sup>10</sup>: 0 = no finding, 1 = mucosal thickening, 2 = partial opacification with liquid accumulation, and 3 = total opacification. The 2 reviewers agreed in 98 of the 105 cases, which resulted in interrater classification agreement higher than 90%.

The Schneiderian membrane thickness was recorded at 3 representative positions (a, b, c) in the coronal plane. The distance b was measured at the deepest point of the recess of the maxillary sinus. The distances a and c were measured 5 mm buccally and palatally based on line b (Fig. 1).

The significance level for all tests was  $p < 0.05$ . All statistical analyses were performed with software (SPSS 17.0, Chicago, IL, USA).

## RESULTS

The mean membrane thickness was calculated for each patient, and the mean overall membrane thickness was calculated for each group (Table 1). There were significant differences between group 2 and group 3. There was no difference between group 1 and the other groups.



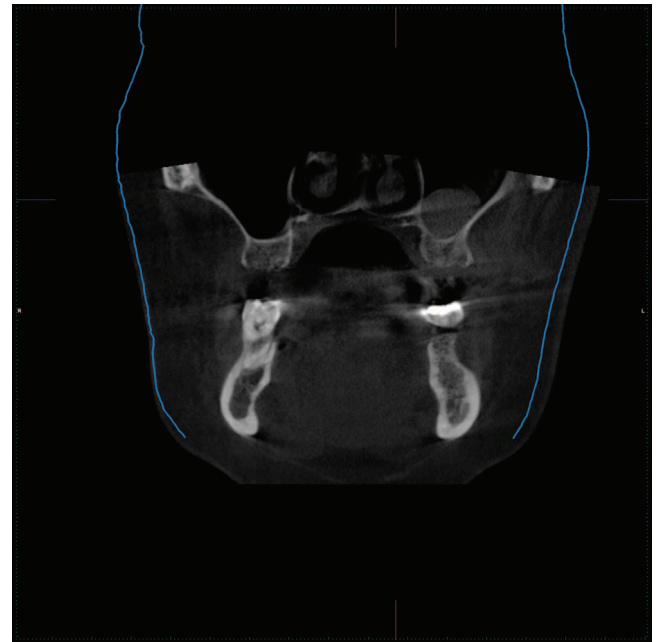
**Figure 2.** An example of acute sinusitis.

The percentages of total opacification were similar in all groups (3%; see Table 2). In all groups, only mucosal thickening had the highest percentage. The highest percentages of mucosal thickening and partial opacification were in Group 3.

### DISCUSSION

The aim of this study was to determine the relation between skeletal malocclusion and maxillary sinus findings. Three types of pathological sinus findings were observed: flat mucosal thickening, polypoid mucosal thickening, and signs of sinusitis (Fig. 2 and 3).

The season during which the CBCT scans were performed may have affected the development of sinus pathologies. One may expect to find higher frequencies in winter or autumn. However, according to Pazera *et al.*,<sup>10</sup> seasons do not affect the frequency of sinus pathologies. The researchers also reported that maxillary sinus findings are not related to gender.



**Figure 3.** An example of polypoid mucosal thickening.

Researchers who performed CT imaging confirmed the high prevalence of incidental findings without clinical symptoms. Havas *et al.*<sup>11</sup> reported that a radiologic abnormality in paranasal sinuses occurred in up to 42.5% of CT scans of asymptomatic patients. Another study reported that patients presenting with symptomatic sinus are more likely to have positive sinus CT findings compared with asymptomatic patients.<sup>12</sup> In our study, we did not consider the clinical history of the scanned patients, because it has been previously revealed that there is weak correlation between radiologic airway findings and clinical symptoms.

Studies using CT and magnetic resonance imaging revealed that the coronal view is appropriate for evaluating the mucosal thickness in the maxillary sinus. The measurements were always performed perpendicular to the underlying bone.<sup>13,14</sup> Two millimeters is an applicable threshold for pathological swellings.<sup>15</sup> Our results confirmed the great interindividual variability related to the Schneiderian membrane thickness, with values ranging from 0.19 to 5.27.

**Table 1.** Descriptions of the groups for Schneiderian membrane

Group	n	Mean	SD	Minimum	Maximum	Analysis of Variance
I	35	1,025	0.43	0.19	1.98	ab
II	35	0.932	0.51	0.08	1.77	a
III	35	1.27	0.36	0.70	2.52	b



**Table 2.** Pathological finding percentages in maxillary sinuses

	Group I	Group II	Group III
0	75	72	51
1	16	16	20
2	6	9	26
3	3	3	3

In our study, no signs of osteomyelitis or bone malignancy were observed. However, these kinds of pathologies with a low incidence rate can be present in a patient group. Bornstein *et al.*<sup>16</sup> revealed a case of Ewing's sarcoma in a young female patient whose CBCT examination showed proliferation of soft tissue in the maxillary sinus.

In our study, there was no statistical difference between Class I and other malocclusion groups in the Schneiderian membrane thickness. However, there was a significant difference between the Class II and Class III groups, meaning that the malocclusion might trigger changes in the sinus membrane thickness. The lowest value for the membrane thickness was recorded in the Class II malocclusion group. These patients may present more respiratory problems caused by the backward mandibular position. Similarly, Nunes and Di Francesco<sup>17</sup> stated that adenoid and tonsil enlargements are more often seen with Class II malocclusion.

### CONCLUSION

Within the limitations of this study, it can be concluded that there is no relation between the pathological sinus findings and skeletal malocclusion. The only statistical difference in the Schneiderian membrane thickness was recorded between the Class II and Class III malocclusion groups. Therefore, a relationship was found between skeletal malocclusion and incidental maxillary sinus findings.

### REFERENCES

- Ludlow JB, Ivanovic M. Comparative dosimetry of dental CBCT devices and 64-slice CT for oral and maxillofacial radiology. *Oral Surg Oral Med Oral Pathol Oral Radiol Endod.* 2008;106:106–114.
- Hujoel P, Hollender L, Bollen AM, Young JD, McGee M, Grosso A. Head-and-neck organ doses from an episode of orthodontic care. *Am J Orthod Dentofacial Orthop.* 2008; 133:210–217.
- Patel K, Chavda SV, Violaris N, Pahor AL. Incidental paranasal sinus inflammatory changes in a British population. *J Laryngol Otol.* 1996;110:649–651.
- Cha JY, Mah J, Sinclair P. Incidental findings in the maxillofacial area with 3-dimensional cone-beam imaging. *Am J Orthod Dentofacial Orthop.* 2007;132:7–14.
- Jani AL, Hamilos DL. Current thinking on the relationship between rhinosinusitis and asthma. *J Asthma.* 2005;42:1–7.
- Engelhardt JF, Yang Y, Stratford-Perricaudet LD, Allen ED, Kozarsky K, *et al.* Direct gene transfer of human CFTR into human bronchial epithelia of xenografts with E1-deleted adenoviruses. *Nat Genet.* 1993;4:27–34.
- Agren K, Nordlander B, Linder-Aronsson S, Zettergren-Wijk L, Svanborg E. Children with nocturnal upper airway obstruction: postoperative orthodontic and respiratory improvement. *Acta Otolaryngol.* 1998;118:581–587.
- Lowe AA, Santamaria JD, Fleetham JA, Price C. Facial morphology and obstructive sleep apnea. *Am J Orthod Dentofacial Orthop.* 1986;90:484–491.
- Sharan A, Madjar D. Correlation between maxillary sinus floor topography and related root position of posterior teeth using panoramic and cross-sectional computed tomography imaging. *Oral Surg Oral Med Oral Pathol Oral Radiol Endod.* 2006;102:375–381.
- Pazera P, Bornstein MM, Pazera A, Sendi P, Katsaros C. Incidental maxillary sinus findings in orthodontic patients: a radiographic analysis using cone-beam computed tomography (CBCT). *Orthod Craniofac Res.* 2011;14:17–24.
- Havas TE, Motbey JA, Gullane PJ. Prevalence of incidental abnormalities on computed tomographic scans of the paranasal sinuses. *Arch Otolaryngol Head Neck Surg.* 1988;114:856–859.
- Jones NS. CT of the paranasal sinuses: a review of the correlation with clinical, surgical and histopathological findings. *Clin Otolaryngol Allied Sci.* 2002;27:11–17.
- Min YG, Lee JW, Shin JS. Radiologic assessment of diseased mucosa of the maxillary sinus after functional endoscopic sinus surgery. *Acta Otolaryngol.* 1994;114:657–662.
- Rak KM, Newell JD II, Yakes WF, Damiano MA, Luethke JM. Paranasal sinuses on MR images of the brain: significance of mucosal thickening. *AJR Am J Roentgenol.* 1991;156: 381–384.
- Cagici CA, Yilmazer C, Hurcan C, Ozer C, Ozer F. Appropriate interslice gap for screening coronal paranasal sinus tomography for mucosal thickening. *Eur Arch Otorhinolaryngol.* 2009;266:519–525.
- Bornstein MM, von Arx T, Altermatt HJ. Loss of pulp sensitivity and pain as the first symptoms of a Ewing's sarcoma in the right maxillary sinus and alveolar process: report of a case. *J Endod.* 2008;34:1549–1553.
- Nunes WR Jr, Di Francesco RC. Variation of patterns of malocclusion by site of pharyngeal obstruction in children. *Arch Otolaryngol Head Neck Surg.* 2010;136:1116–1120.